



New York University School of Medicine
Division of Medical Oncology



Langone Medical Center

Topical TLR7 agonist Imiquimod can induce immune-mediated rejection of breast cancer skin metastases

Sylvia Adams, MD

Assistant Professor of Medicine
Breast Cancer and Cancer Immunotherapy Programs
NYU Cancer Institute

SITC 26th Annual Meeting
November 5, 2011



New York University School of Medicine
Division of Medical Oncology



Langone Medical Center

Presenter Disclosure Information

Sylvia Adams

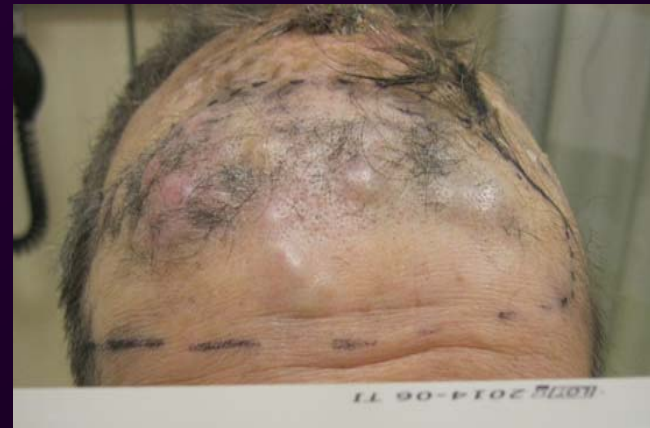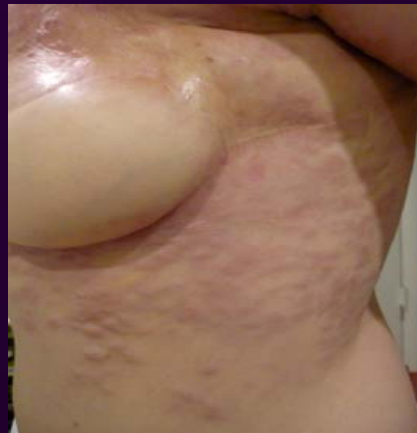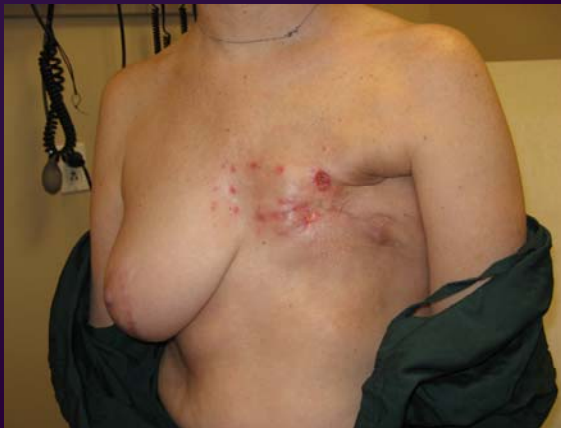No Relationships to Disclose

Will discuss off label use for imiquimod
(indication in presentation is not currently approved by the FDA)

Background


Skin metastases of solid tumors remain a debilitating experience for patients and a therapeutic challenge for the treating physician.

Breast cancer is the most common tumor, excluding melanoma, to metastasize to the skin in women and often manifests as chest wall recurrence after mastectomy.



Purpose

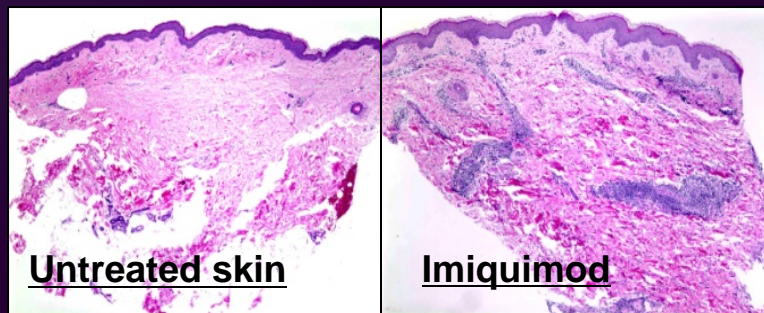
- △ Novel treatment approaches needed for skin metastases.
- △ Imiquimod has profound immunomodulatory effects on the tumor environment, and can induce immune-mediated rejection of primary skin malignancies when topically applied.
- △ Anecdotal evidence for complete regression of BC metastases.



We tested the hypothesis that topical IMQ can stimulate local anti-tumor immunity and induce the regression of breast cancer skin metastases in a prospective trial.

Imiquimod

- ❑ TLR7 activation via the agonist IMQ enhances DC maturation and antigen presentation and facilitates tumor rejection by enhancing Th1 skewing and T cell homing to the tumor.
- ❑ Clinical use of IMQ: FDA approved for HPV-related warts, actinic keratosis and basal cell carcinoma. Off label use for melanoma (primary and metastatic).
- ❑ Induction of immune responses to tumor-associated antigens administered simultaneously into healthy skin of cancer patients.



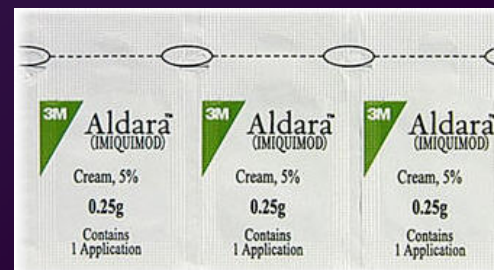
Panelli, et al, Genome Biol 2007
Adams et al, J Immunology, 2008
Adams, Immunotherapy, 2009
Narayan et al, J Invest Derm 2011

Patients and Methods

- ❑ Measurable skin metastases not suitable for definitive surgical resection and/or radiotherapy (≥ 18 yo, biopsy-proven breast cancer, adequate PS, bone marrow and organ function, IC).
- ❑ Primary objective: local tumor response rate (clinical response) of skin metastases treated with topical IMQ.
- ❑ Secondary objectives: safety and immunological correlates. Punch biopsies of tumor obtained pre- and post-treatment for in situ TIL analysis by IHC, supernatant cytokine analysis and TIL immunophenotyping.

Treatment

Imiquimod 5%



- Topically applied to lesions overnight
- 5 d/week for 8 weeks (sBCC regimen)
- One packet for areas up to 100 cm²; max of 6 packets/day

Concurrent systemic cancer therapy only allowed if on stable regimen for >12 weeks and skin metastases non-responsive.



Demographics

Patient and Tumor Characteristics

N = 10

| | | |
|-------------|---------------------------|---------|
| Race | Caucasian | 6 (60%) |
| | Non-Caucasian | 4 (40%) |
| Age | 44-71, Median = 50 | |
| Grade | Poorly differentiated | 8 (80%) |
| | Moderately differentiated | 1 (10%) |
| | N/A (lobular) | 1 (10%) |
| HR Status | Positive | 8 (80%) |
| | Negative | 2 (20%) |
| Her2 Status | Positive | 6 (60%) |
| | Negative | 4 (40%) |



Tumor sites and prior treatments

N = 10

| | | |
|---|---|------------|
| Presentation | Chest wall recurrence (4 with reconstruction) | 7 (70%) |
| | Skin involvement of neglected and metast BC | 3 (30%) |
| Sites of metastases | Chest wall/skin only | 2 (20%) |
| | + Bone/LN mets | 5 (50%) |
| | + Lung/Pleura/Adrenal | 3 (30%) |
| Prior treatment for recurrent or metastatic disease | Yes | 10 (1000%) |
| | Chemotherapy +/- anti Her2 | 7 |
| | Bevacizumab | 4 |
| | Endocrine therapy +/- anti Her2 | 8 |
| | Surgery | 4 |
| | Radiotherapy | 5 |
| | Hyperthermia and investigational compounds | 2 |
| Concurrent therapy (without prior response) | None | 3 (30%) |
| | Chemotherapy +/- anti Her2 | 2 (20%) |
| | Endocrine therapy +/- anti Her2 | 5 (50%) |



Safety

- ❑ Well tolerated, transient local and systemic side effects ~ IMQs immunomodulator
- ❑ At max. dose: high grade fever, fatigue and depression ~ systemic IFNa effect
- ❑ Local and systemic AE manageable with frequency reduction (TIW)

| CTC AE v 3.0 | | Grade 1 | Grade 2 | Grade 3/4 |
|--|-------------------------------------|----------|----------|-----------|
| Dermatologic (local at tumor site) | | | | |
| | Local Pain | 2 | 1 | 0 |
| | Inflammation/Redness | 2 | 1 | 0 |
| | Infection | 1 | 0 | 0 |
| | Itching | 3 | 0 | 0 |
| | Burning | 1 | 0 | 0 |
| | Desquamation/ulceration with oozing | 2 | 1 | 0 |
| | Total patients | 5 | 2 | 0 |
| Systemic (constitutional, mood, gastrointestinal) | | | | |
| | Depressed Mood | 0 | 1 | 0 |
| | Fatigue | 0 | 1 | 0 |
| | Myalgias | 1 | 1 | 0 |
| | Arthralgias | 1 | 0 | 0 |
| | Fever/chills | 1 | 1 | 0 |
| | Lymphadenopathy | 1 | 0 | 0 |
| | Nausea/vomiting | 0 | 1 | 0 |
| | Dehydration | 0 | 1 | 0 |
| | Total patients | 2 | 2 | 0 |

Results

Anti-tumor efficacy

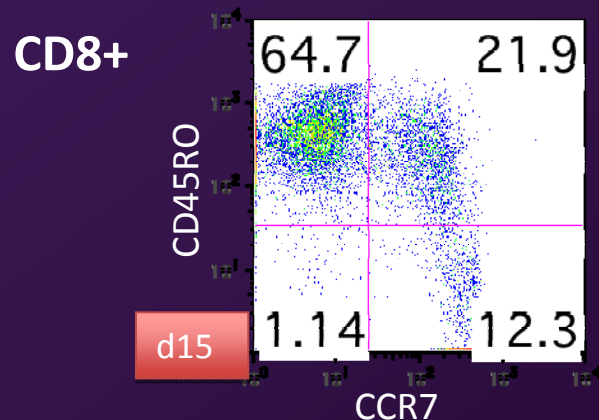
- ❑ 2/10 patients achieved a clinical PR (>50% reduction) to topical IMQ
- ❑ 2 progressed with new skin lesions
- ❑ 6 remained stable, two in clinical remission on subsequent regimen

Immune correlates

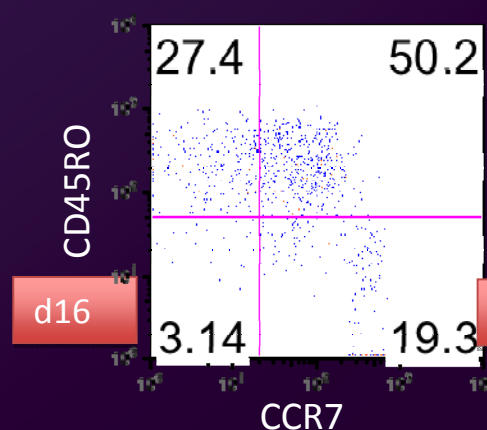
- ❑ Varying pre-existing lymphocytic infiltrates (<5 to 65 CD3+ cells/HPF)
- ❑ No consistent changes in TIL numbers, intratumoral cytokine milieu
- ❑ In the clinical responders: changes c/w an immune-mediated anti-tumor response

TIL cultures successful from 7/20 biopsies, in one patient before and after

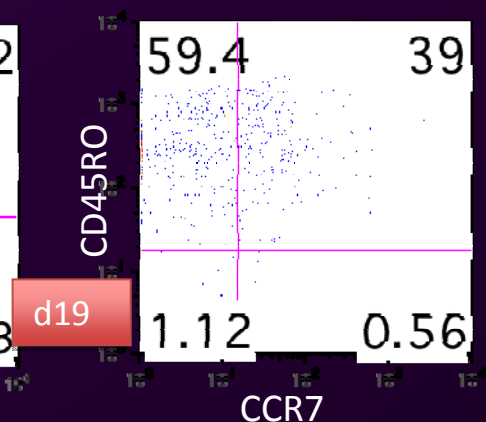
PBMC post-IMQ



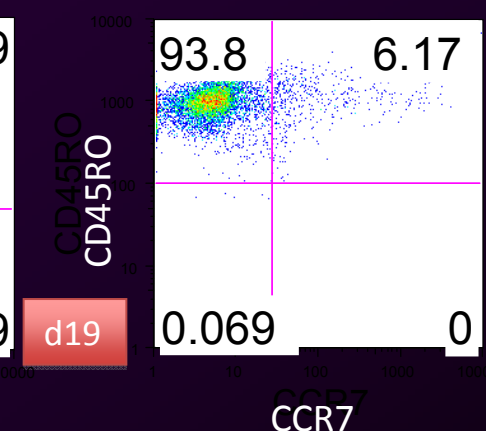
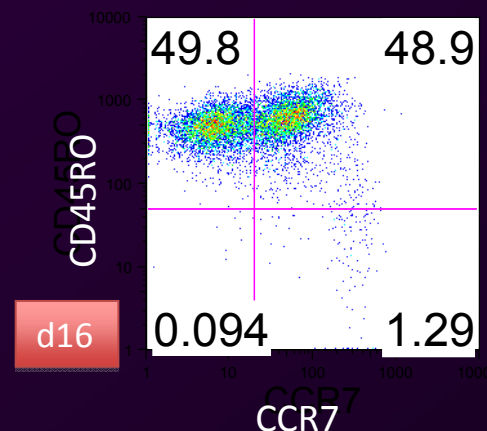
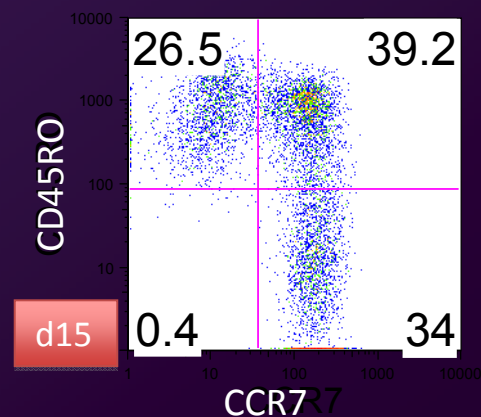
TIL pre-IMQ



TIL post-IMQ



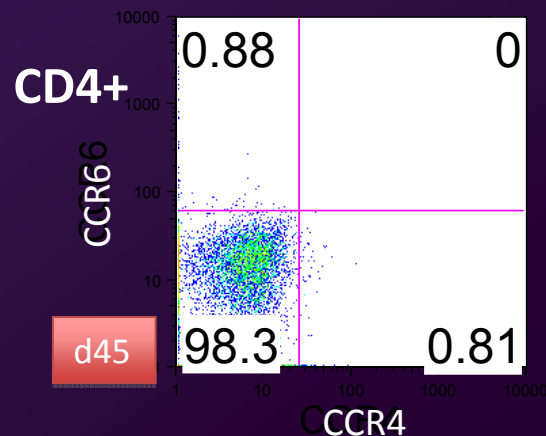
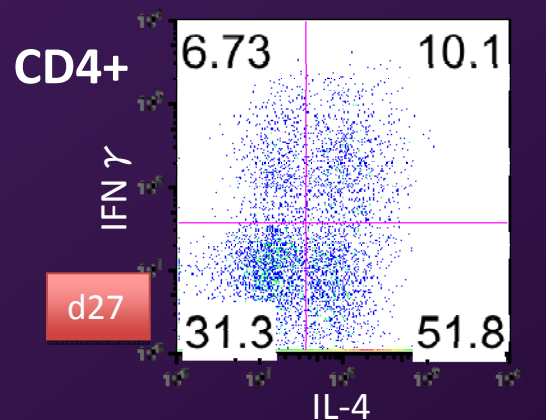
CD4+



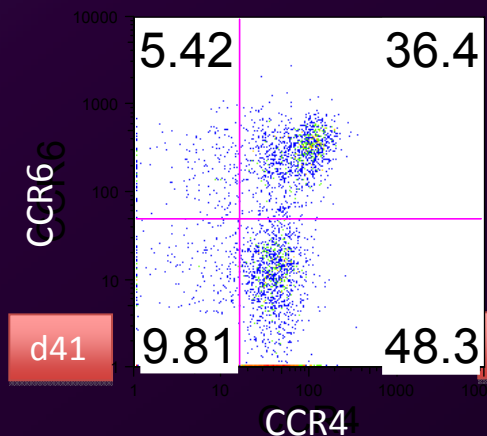
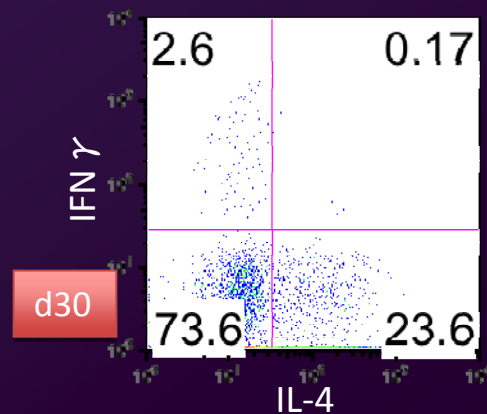
Culture: RPMI, 10% FBS, gentamicin and IL2 (10ng/ml)
Days of culture (red box)



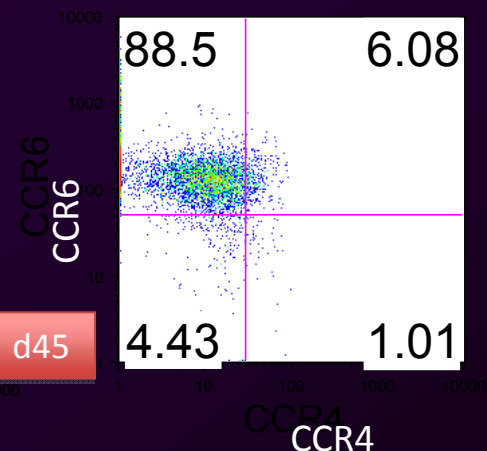
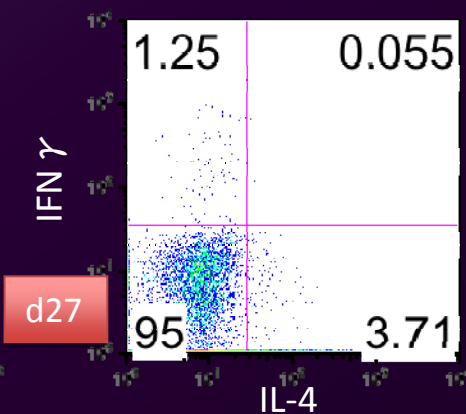
PBMC post-IMQ



TIL pre-IMQ



TIL post-IMQ

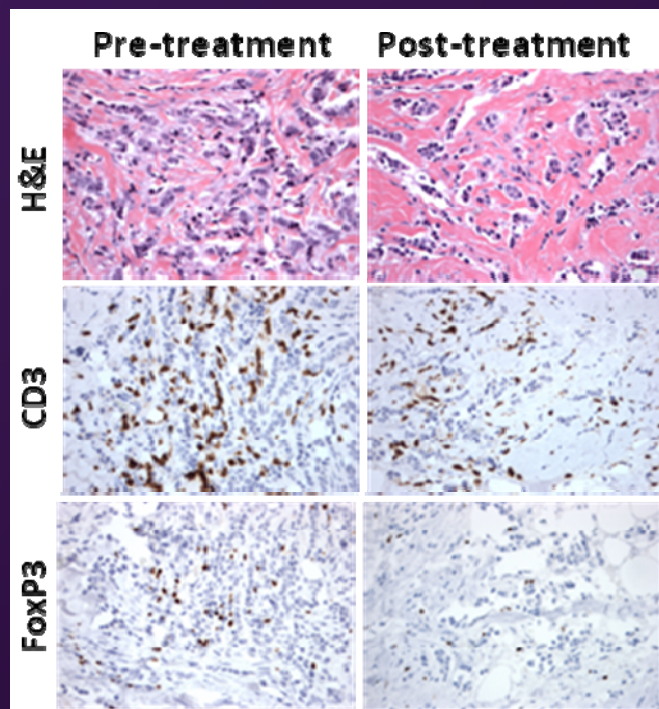


Culture: RPMI, 10% FBS, gentamicin and IL2 (10ng/ml)
Days of culture (red box)

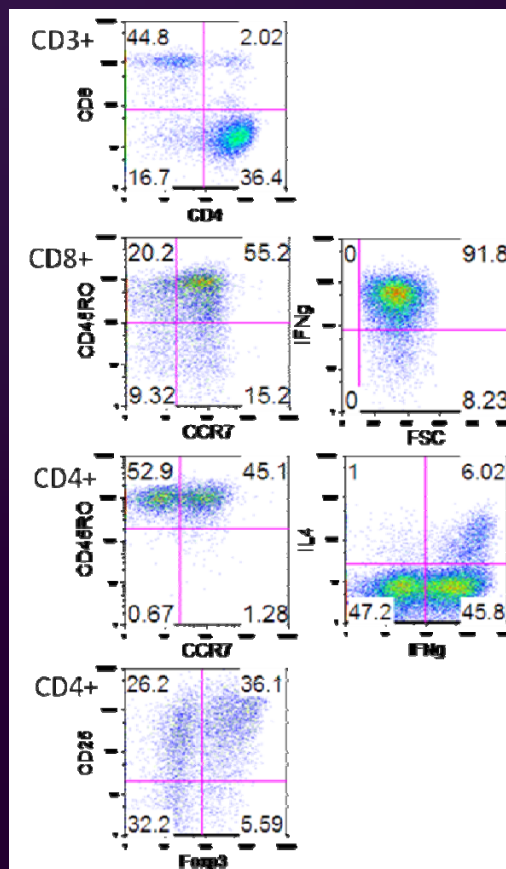
Tumor supernatant
Increase in pro-inflammatory
cytokines

Responder 2

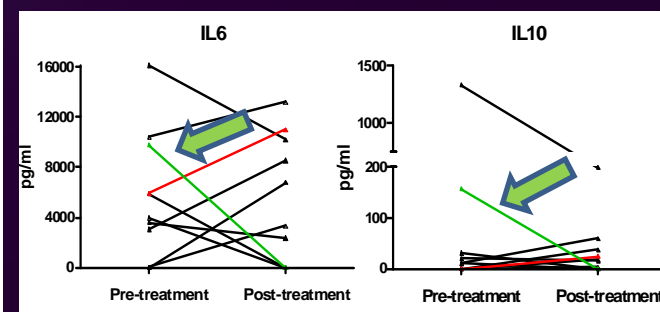
59F with chest wall recurrence, LN and bone mets, HR+, Her2-



Moderate T cell infiltrate before.
Reduction of FoxP3 T cells while
CD4 counts remain unchanged.



TIL pre-treatment (d 8 of Cx):
predominately CD4+ T cells,
including Th2 and Tregs.
No TIL after treatment.



Tumor supernatant: decreased
counter-regulatory cytokines

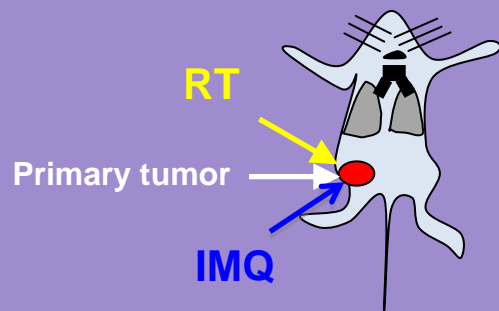


Conclusions and future directions

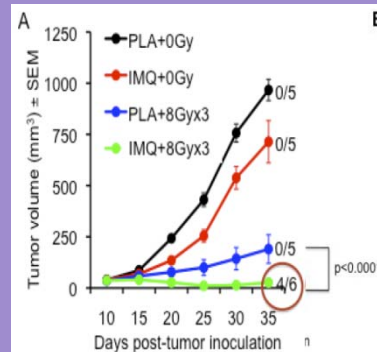
- ❑ Topical IMQ is able to induce immune changes within the treated skin metastases with evidence of tumor rejection.
- ❑ To improve efficacy we have studied the combination with local radiotherapy in preclinical models.
 - Evidence for synergy with immunotherapies (Demaria, et al, Clin Can Res, 2005)
 - Common treatment modality breast cancer

Topical IMQ with concurrent local RT

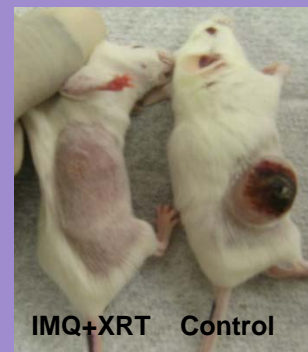- BALB/c mouse-derived TSA mammary adenocarcinoma: poorly immunogenic tumor that mimics the clinical presentation of chest wall recurrence, forming subcutaneous nodules and ulcerating through the skin.
- Synergy of topical IMQ + local RT with complete regression of treated tumors and prolonged survival in TSA tumor bearing mice.



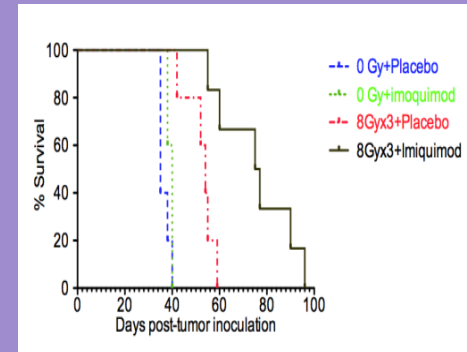
S.c. syngeneic TSA (1×10^5).
Topical IMQ (5%) or placebo 3x/week.
Mock RT or 3x 8 Gy (d 12, 13 and 14)



Tumor growth overtime
(5-6 mice/group)



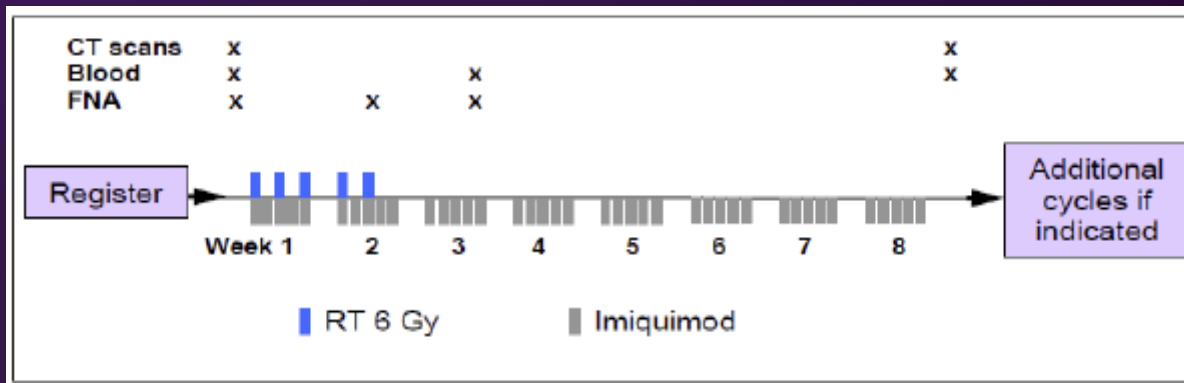
Complete regression
with topical IMQ +
local RT



Kaplan Meier curves:
combination treatment
with superior survival

- Systemic anti-tumor effects observed in the subcutis (TSA) and lung metastases (4T1 model, also poorly immunogenic tumor, which sheds spontaneous systemic metastases to the lungs causing death of the animals)

Current trial (Phase I/II of IMQ/RT)



Primary endpoint:

- Systemic anti-tumor response to local IMQ+RT (shrinkage of distant metastases)

Secondary endpoints:

- Safety
- Local tumor regression
- Tumor-specific T cell responses
- Tumor immune signature of rejection (collaboration with Drs. Marincola and Wang)

Supported by NCI R01 (thanks Dr. Disis for valuable input on design and choice of study section)



Acknowledgements

Collaborators

Sandra Demaria, MD
Nina Bhardwaj, MD, PhD
Silvia Formenti, MD
Derya Unutmaz, MD
Lina Kozhaya, MSc
Judy Goldberg, ScD

Graceway Pharmaceuticals

Tze-Chiang Meng, MD

Patients

NYU Cancer Institute

Referring physicians
Clinical Trials Office
Core Laboratories

Grant support

National Cancer Institute K23
NYUCI Translational Award



New York University School of Medicine
Division of Medical Oncology



Langone Medical Center

Thank you!



**New York University
School of Medicine**



**Bellevue Hospital
Medical Center**



New York University School of Medicine

Division of Medical Oncology

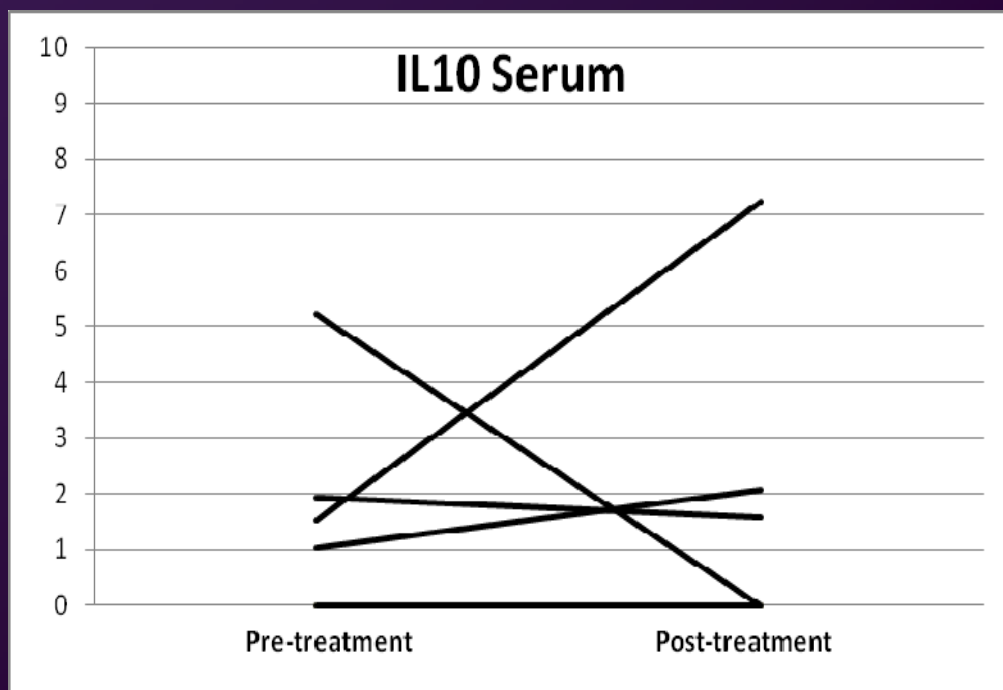


Langone Medical Center

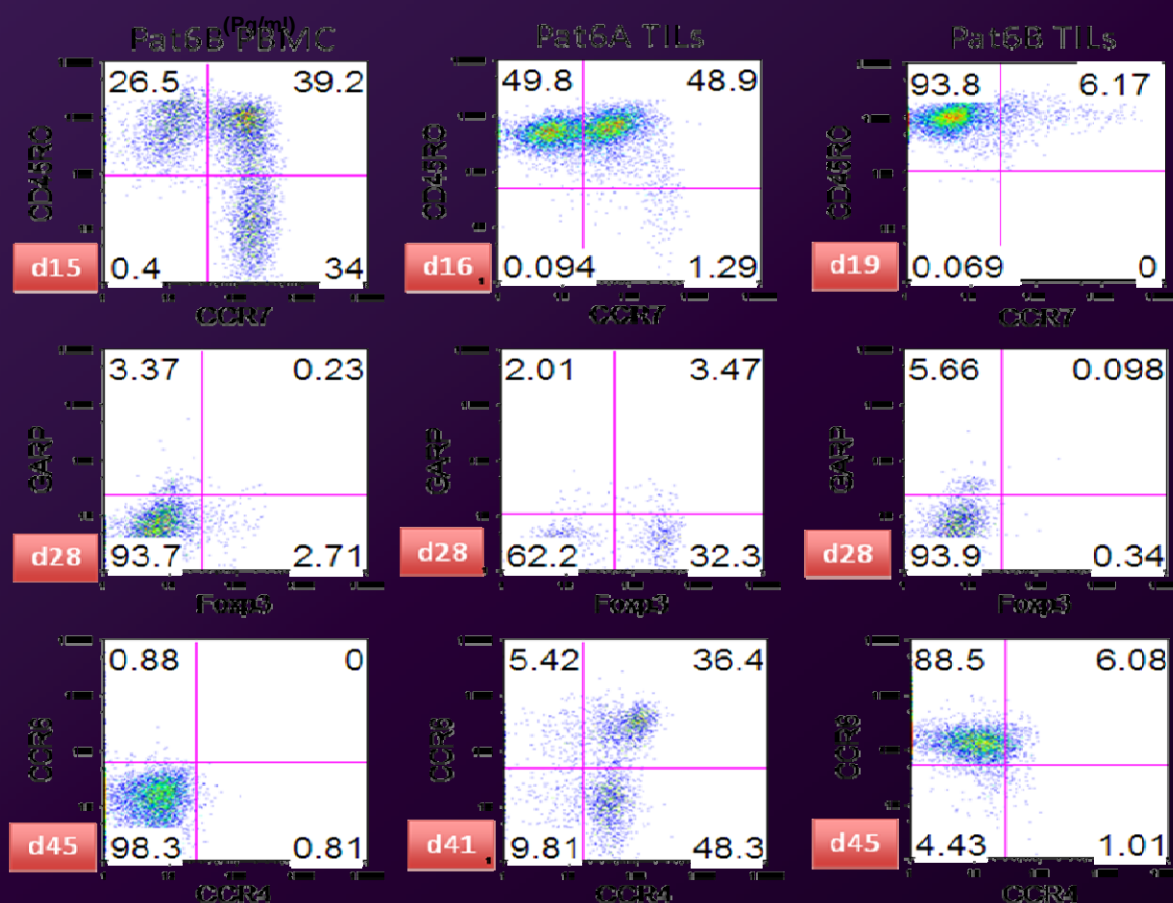


Additional slides

(Pg/ml)



Additional slides

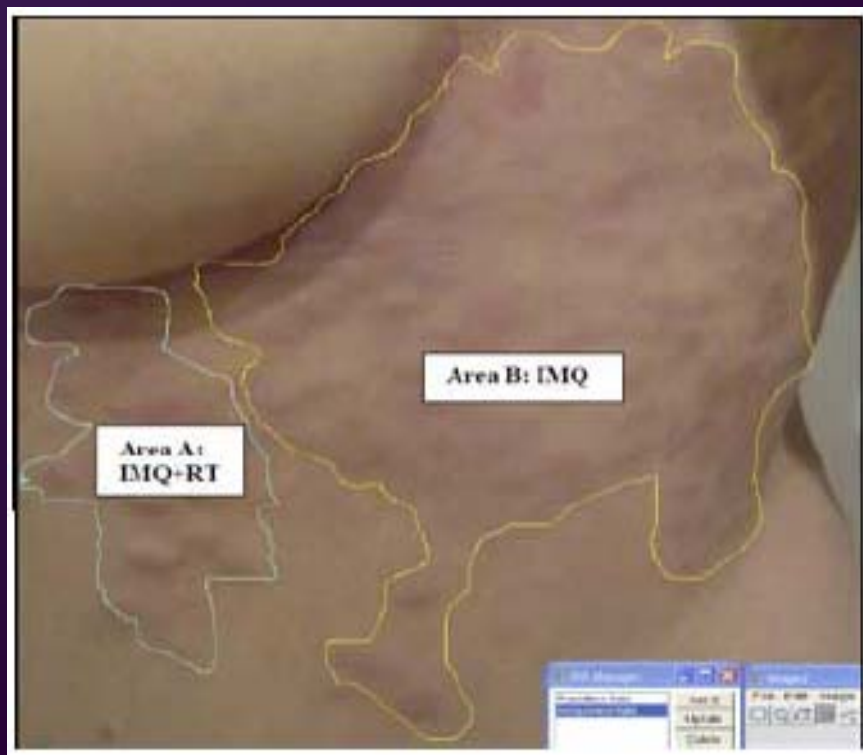




New York University School of Medicine Division of Medical Oncology



Langone Medical Center





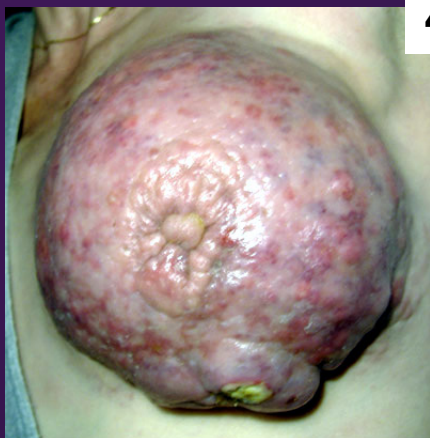Additional slides

(Pg/ml)

| Response | $ROI^{change} = (ROI^{post-treatment} / ROI^{pre-treatment}) \times 100\%$ | Patients (%) |
|----------|--|--------------|
| CCR | Absence of any detectable residual disease | none |
| PR | >0 - <50% | 2 (20%) |
| SD | ≥ 50 - <100% | 5 (50%) |
| NR | ≥ 100 – <125% | 1 (10%) |
| PD | $\geq 125\%$ or new skin lesions | 2 (20%) |



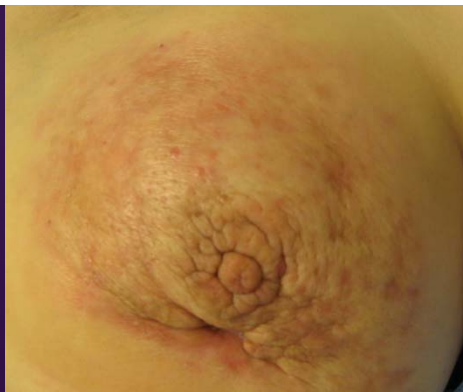49 Caucasian F with SD on IMQ now in clinical CR



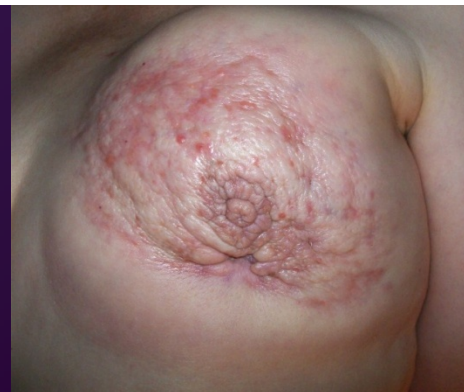September 2009

Diagnosis of Stage IV
Breast cancer (T4N3M1)
Malign. Hypercalcemia

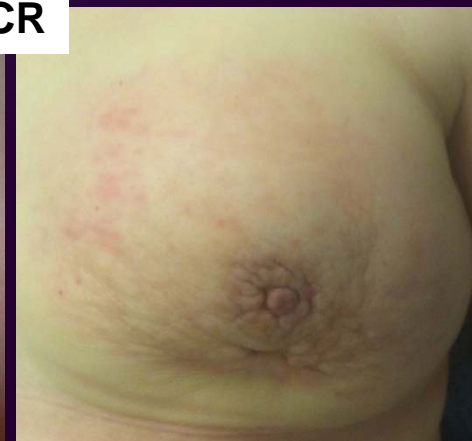Neglected breast ca
Pectoralis invasion
Sternum destruction
Bone metastases
Lung metastases



April 2010



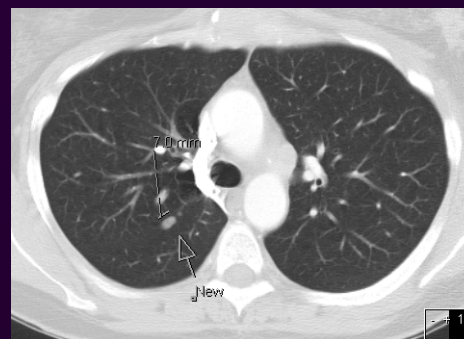
June 2010



September 2010

Complete clinical
Remission with
resolution of bone,
lung metastases and
breast primary

Ongoing CR >1 year



CA 27-29: **430** U/ml → **37** → **65** → **67** → **9** (normal)
Poorly diff, ER+, Her2-

Paclitaxel
Bevacizumab

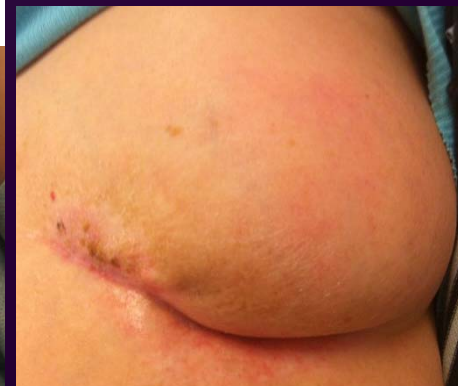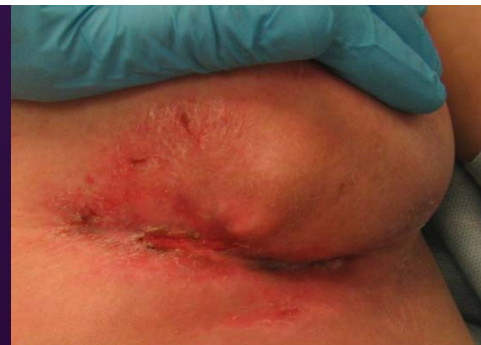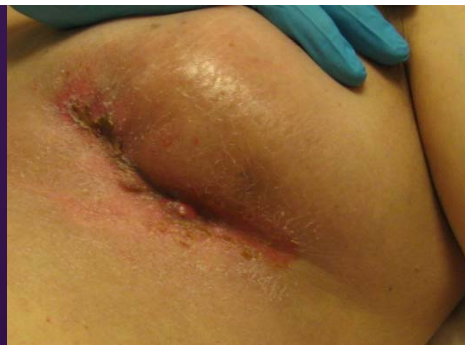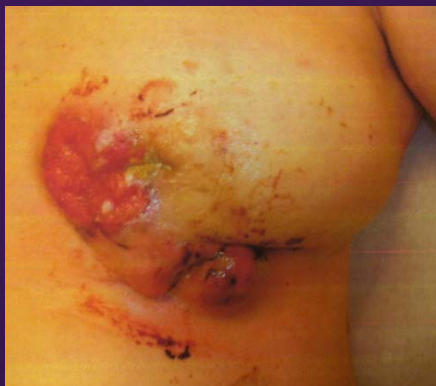LH-RH- agonist
and Tamoxifen

+ Imiquimod x 8 wks

Fulvestrant



50 Asian F with SD on IMQ now in clinical CR



August 2009

Diagnosis of Stage IV
Breast cancer (T4N2M1)

Neglected, fungating breast ca
Pectoralis involvement
Mediastinal and axill LN
Adrenal metastasis

March 2010

May 2010

October 2011

Complete clinical
remission with resolution
of LN and normalization of
glucose avidity in breast
and adrenal gland

